

*Short Communication*

**MANAGEMENT OF DERMATOLOGICAL LESIONS ASSOCIATED  
WITH *BABESIA GIBSONI* IN DOGS**

S. Sivajothi<sup>1\*</sup>, B. Sudhakara Reddy<sup>2</sup>

*Received 16 June 2017, revised 10 November 2017*

**ABSTRACT:** Three dogs were presented to the clinic with the history of recurrent dermatological abnormalities, fever, dyspepsia, lethargy and progressive weight loss. Dermatological findings observed were dry exfoliations, alopecia, hemorrhagic spots over abdomen and groin regions, inter digital ulcerative lesions, hyperkeratosis of digital pads, brittleness of nails and pododermatitis. Microscopic examination of the stained peripheral blood smears revealed the *Babesia gibsoni* organisms in the erythrocytes. Dogs showed anaemia, leucopaenia, thrombocytopenia, hyper globulinemia and low albumin levels. Uneventful recovery was recorded after treatment with intra muscular administration of two doses of diminazene aceturate @ 7.0 mg/kg body weight and oral administration of clindamycin @ 25 mg/kg body weight twice in a day. Improvement in the clinical findings was noticed by the three days of therapy and complete dermatological clinical cure was obtained after two months of therapy.

**Key words:** Babesia, Dog, Clindamycin, Pyoderma.

Canine recurrent pyoderma is an important frustrating clinical presentation in routine clinical practice. Dogs with uncorrected underlying factors are repeatedly suffered with pyoderma (Reddy *et al.* 2014). Among the different types of vector borne diseases in dogs, babesiosis is clinically significant disease. It is transmitted by *Dermacentor reticulatus*, *Rhipicephalus sanguineus*, *Haemaphysalis elliptica* in the world wide. It is caused by either *Babesia canis* or *Babesia gibsoni*, based on the geographic location. *Babesia gibsoni* is a small parasite that appears as ring forms or pyriform shape bodies within the red blood cells. There are several reports of clinical manifestation of babesiosis in dogs due to *Babesia canis* and *Babesia gibsoni* in India (Schoeman 2009). Common clinical findings recorded in canine babesiosis are anorexia, fever, lethargy and involvement of the kidney and liver failure (Sivajothi *et al.* 2014). But, dermatological manifestations are not validated in diagnosis of babesiosis in dogs. Reports on the development of the dermatological lesions due to *Babesia gibsoni* are scarce (Tarello 2003). The present paper describes about the management of recurrent dermatological manifestations in association with the Babesiosis in dogs.

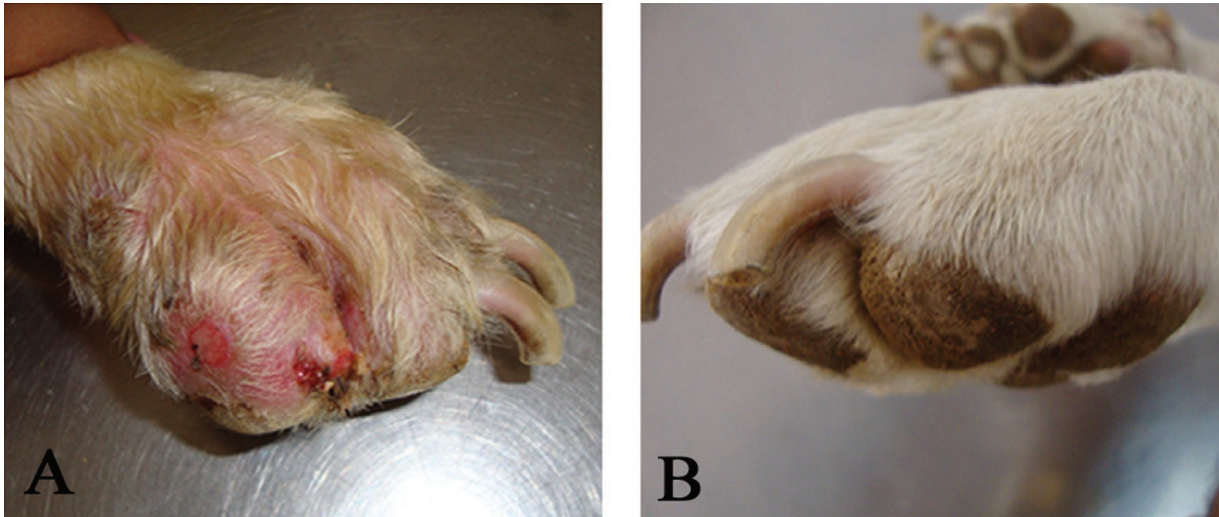
**The study**

During the three years period (2013 to 2016), three

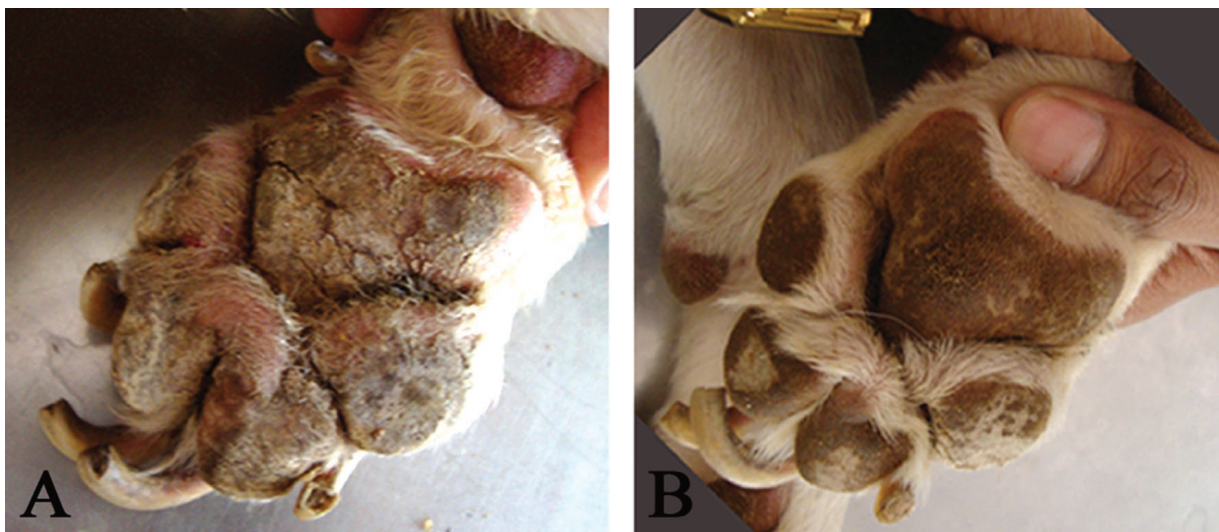adult dogs were identified suffering with recurrent dermatological issues in relation to the babesiosis in the College of Veterinary Science, Proddatur. All the dogs were presented to the clinic with history of repeated skin problems, intermittent fever, dyspepsia, lethargy and progressive weight loss since from two to four months. Clinical examination of the dogs revealed elevated rectal temperature, heart rate, respiratory rate, congestion of conjunctival mucus membranes with pale buccal mucus membranes and generalized lymphadenopathy. Dermatological findings observed were dry exfoliations, alopecia, hemorrhagic spots over abdomen and groin regions, inter digital ulcerative lesions (Fig.1A), hyperkeratosis of digital pads, brittleness of nails and pododermatitis (Fig.2A). Urine analysis, fecal examination did not revealed any abnormalities. Superficial and deep skin scrapings, impression tape smears and hair pluck examination did not revealed any mite infestation. Peripheral blood smears and whole blood was collected for laboratory analysis. Hematology revealed the value of haemoglobin (8.6 - 9.2 g/dL), packed cell volume (26 - 29%), total erythrocyte count (4.2 - 4.6 X10<sup>6</sup>/µl), thrombocyte count (86 - 124 X10<sup>3</sup>/µl) and total leucocytes count (4300 - 6200 /µl). Serum biochemistry revealed, normal serum protein (6.6 - 7.2 g/dL), hyper globulinemia (4.8 - 5.2 g/dL), low albumin (1.8 - 2.0 g/dL), normal ALT (28 - 36 IU/L), creatinine (1.0 - 1.8 mg/

<sup>1</sup>Assistant Professor, Department of Veterinary Parasitology, <sup>2</sup> Assistant Professor, Veterinary Medicine, Department of Veterinary Clinical Complex, College of Veterinary Science, Proddatur, YSR Kadapa district, Sri Venkateswara Veterinary University, Andhra Pradesh, India.

\*Corresponding author. e- mail: sivajothi579@gmail.com



**Fig.1. Ulcerated skin lesions (A- Before treatment; B- After treatment).**



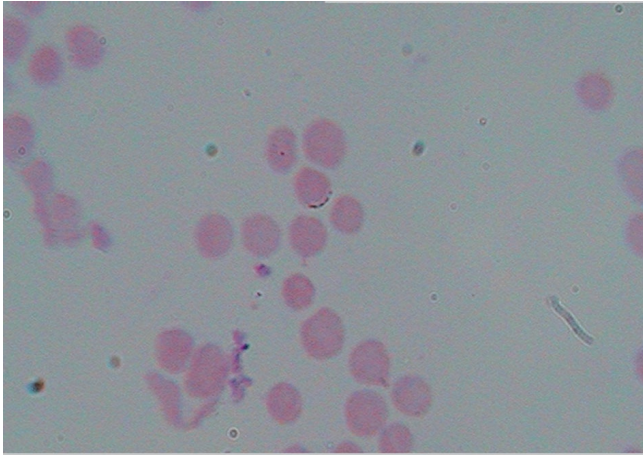
**Fig. 2. Podo-dermatitis (A - Before treatment; B - After treatment).**

dL) and blood urea nitrogen (26 - 43 mg/dL) levels. Microscopic examination of the Leishmans's stain peripheral blood smears revealed presence of the *Babesia gibsoni* organisms. *Babesia gibsoni* organisms were identified based on their morphology consist of the single merozoites with in the red blood cells (Fig. 3).

All the dogs were successfully treated with two doses of injection diminazene aceturate @ 7.0 mg/kg body weight, intra muscularly at one week interval gap, oral administration of the clindamycin @ 25 mg/kg body weight, twice in a day for three weeks, daily oral administration of iron and liver tonics and weekly twice shampooing with benzyl peroxide. Following therapy, dogs were free from fever by the third day, had improved appetite and general activity within two weeks of treatment. By four weeks of therapy, the dogs were started taking food normally and free from lymphadenopathy. Disappearance of erythematous lesions, healing of ulcerative lesions (Fig.1B), free from onychogryphosis

and softening of hard pads (Fig. 2B) was noticed during the period of observation.

In the present study, canine babesiosis was diagnosed based on the peripheral blood smear examination. Anemia observed could be due to decreased erythropoiesis, a sequel to the chronic form of the disease or due to immune-mediated destruction of erythrocytes, or both. Thrombocytopenia may have developed as a result of circulatory immune complexes, auto antibodies, splenic pooling or bone marrow suppression. Due to development of the immunosuppression, concurrent dermatological signs may be observed in the present study (Reddy *et al.* 2016). Recommended conventional therapy for babesiosis includes injection of diminazene aceturate @ 3.5 mg/kg SC or IM, but *B.gibsoni* are very difficult to eliminate completely (Schoeman 2009). Combination of atovaquone and azithromycin and combination of clindamycin, metronidazole and doxycycline was reported by the



**Fig. 3. *Babesia gibsoni* organisms in the erythrocytes – Red blood cells showing the single merozoites (signet-ring form) (100X).**

previous researcher (Nandini *et al.* 2016). But, in the present study, two doses of intra muscular administration of diminazine aceturate along with oral administration of clindamycin were carried out. Successful management of present condition with clindamycin was reported in concurrence with the previous studies (Wulansari 2003). In the present study, clindamycin was selected to stimulate the humoral and cellular immunity against babesiosis and results in improvement in the dermatological manifestations.

#### **ACKNOWLEDGEMENT**

The authors are thankful to the authorities of the Sri Venkateswara Veterinary University for the facilities provided during the study.

#### **REFERENCES**

- Nandini MK, Vishwakarma P, Kamra CA (2016) New therapeutic protocol for canine babesiosis: A case report. *J Dairy Vet Anim Res* 3(3): 00082.
- Reddy BS, Kumari KN, Rao VV, Rayulu, VC, Sivajothi S (2014) Efficacy of enrofloxacin in the treatment of recurrent pyoderma in dogs. *J Advanced Vet Res* 4(3): 108 - 112.
- Reddy BS, Sivajothi S, Reddy LSSV, Raju KGS (2016) Clinical and laboratory findings of *Babesia* infection in dog. *J Parasit Dis* 40(2): 268 - 272.
- Schoeman JP (2009) Canine babesiosis. *Onderstepoort J Vet Res* 76(1): 59 - 66.
- Sivajothi S, Reddy BS, Rayulu VC and Venkatasivakumar R (2014) Babesiosis in dogs: A report of two different cases. *Advanc Applied Sci Res* 5(3): 276 - 279.
- Tarello W (2003) Concurrent cutaneous lesions in dogs with *Babesia gibsoni* infection in Italy. *Revue Med Vet* 154 (4): 281- 287.
- Wulansari R, Wijaya A, Ano H, Horii Y, Nasu T (2003) Clindamycin in the Treatment of *Babesia gibsoni* Infections in Dogs. *J Am Anim Hosp Assoc* 39(6): 558 - 562.

**\*Cite this article as:** Sivajothi S, Reddy BS (2017) Management of dermatological lesions associated with *Babesia gibsoni* in dogs. *Explor Anim Med Res* 7(2): 213-215.