

Short Communication

HISTOPATHOLOGICAL DETECTION OF THE LARVAL STAGE OF *TAENIA TAENIAEFORMIS* (STROBILOCERCI) AND ITS ASSOCIATED LESIONS IN LIVER OF LABORATORY RATS: CASE REPORT

Remigius Ibe Onoja^{1*}, Idika Kalu Idika², Ikenna Onyema Ezeh², Clifford Nwabugwu Abiazute³

Received 17 February 2017, revised 10 May 2017

ABSTRACT: Histopathological examination of liver tissues of rats maintained in laboratory condition showed the presence of strobilocerci of *Taenia taeniaeformis*. Infiltration of mononuclear cells such as plasma cells, lymphocytes, macrophages and occasional eosinophils were seen. Active fibroplasia was found in the surrounding tissues. The finding is having importance in zoonotic effects and also for possibility of alteration of result of biomedical research works.

Key words: Rats, *Taenia taeniaeformis*, Strobilocercus, Histopathology, Liver.

Taenia taeniaeformis is the larval stage of a cestode parasite that occurs worldwide in the small intestine of cats and related carnivores (Bowman 2007). The larval stage, strobilocercus, has a terminal bladder and a rather long segmented body crowned with the scolex that looks very similar to that found in the adult form. The known intermediate hosts of the cestode are rodents and occasionally the lagomorphs (McInnes 2014, Singh and Arya 2015). Cats (both domestic and wild) and related carnivores become infected when they prey on rodents harboring the strobilocercus stage of the tape worm. Rodents acquire the infection when they ingest the eggs of *T. taeniaeformis* through contaminated feed and water. This is followed by the hatching of the eggs into larva which migrates through the intestinal wall of the rodent and develops into strobilocerci in the liver of the rodent. The life cycle becomes completed when the domestic or wild cats consume any of the infected species of rodents. This is the first report of this parasite in a laboratory animal in Nigeria even though it has been reported in other countries in rodents like wild rats (*Rattus norvegicus*) in the West Indies (Chikweto *et al.* 2009), Korea (Seong *et al.* 1995), Serbia (Kataranovski 2011), in wild mice in India (Malsawmtluangi *et al.* 2011), in rats in Colombia (Duque *et al.* 2012). Although infection

in rats are said to be harmless and subclinical, the zoonotic potential of the parasite and possible alteration of research results for this reason need exposure to the biomedical research community. As the cases were detected during study of rats before use in other experiments related with some toxicological studies, epidemiology and need for appropriate control measures demand more attention of the research communities.

Procedure

A batch of 10% buffered formalin fixed liver samples for a toxicological study, brought to the histopathology unit of the Department of Veterinary Pathology and Microbiology, University of Nigeria, Nsukka for examination. The samples were dehydrated in ascending grades of ethanol, cleared in chloroform overnight, infiltrated and embedded in molten paraffin wax. The blocks were later trimmed and sectioned at 5 microns. The sections were de-paraffinized in xylene, taken to water and subsequently stained with Haematoxylin and Eosin (H and E) for light microscopy.

Finding of the study

Histopathological examination of some of the slides revealed the presence of *T. taeniaeformis*

¹Department of Veterinary Pathology and Microbiology, Faculty of Veterinary Medicine, University of Nigeria, Nsukka, Nigeria.

²Department of Veterinary Parasitology and Entomology, Faculty of Veterinary Medicine, University of Nigeria, Nsukka, Nigeria.

³Department of Veterinary Anatomy, Faculty of Veterinary Medicine, University of Nigeria, Nsukka, Enugu State, Nigeria.

*Corresponding author. e - mail: remigius.onoja@unn.edu.ng

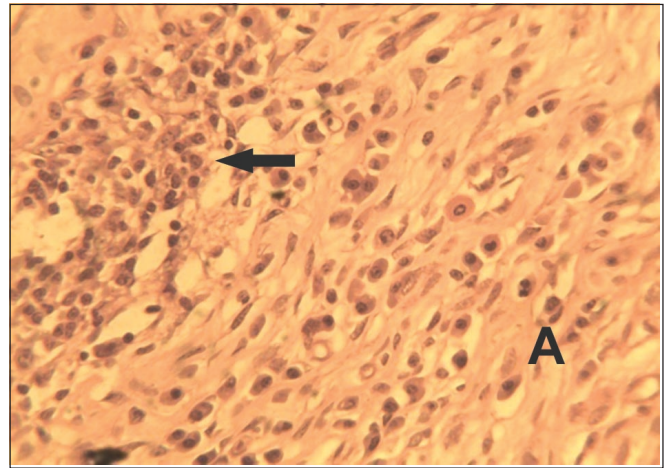
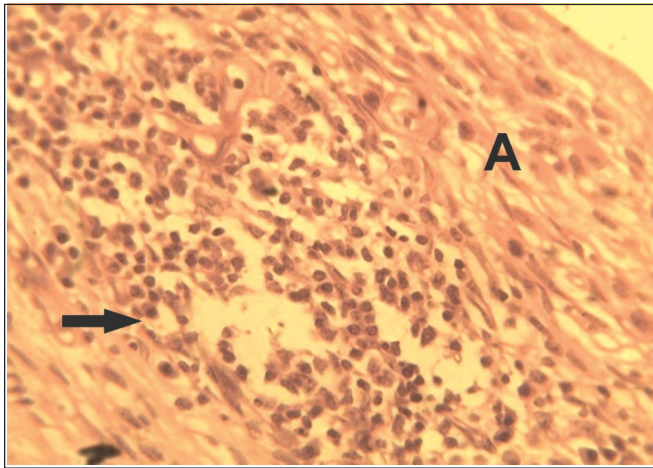


Fig. 1. Photomicrograph of the fibrous connective tissue capsule (A) surrounding the parasite showing extensive zone of inflammatory cells infiltration comprising lymphocytes, plasma cells, macrophages, eosinophils (black arrows). H and E X 400.

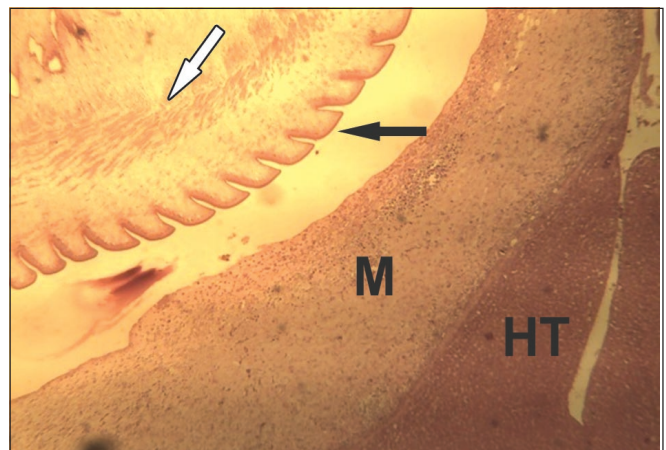
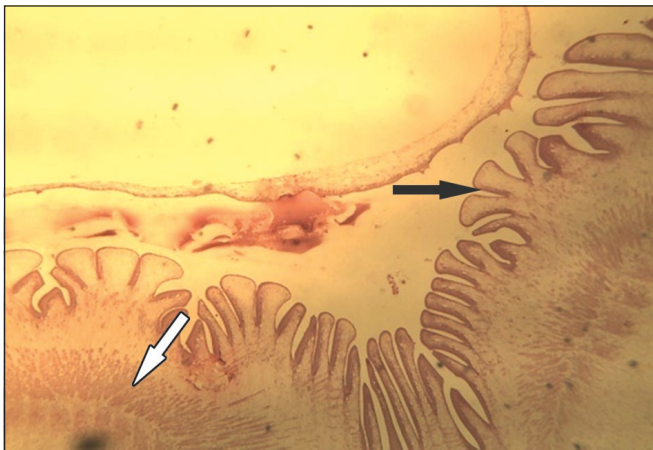

Fig. 2. Photomicrograph of cyst showing a single metacestode with cuticle (black arrows), muscle strands (white arrows) surrounded by a thick fibrous connective tissue capsular wall (M). The zone of normal hepatic tissue (HT) is seen. H and E X 100.

strobilocysticerci. A detailed microscopic study on liver sections of one of the groups revealed cross section of parasites surrounded by a fibrous connective tissue capsule with extensive zone of inflammatory cells infiltration comprising lymphocytes, plasma cells, macrophages, eosinophils and fibrous connective tissue metaplasia (Fig. 1 and Fig. 2). The lesions were varied in severity with some areas still having healthy hepatocytes adjacent to affected areas surrounding the cysts while hepatocytes in some of the affected areas were vacuolated. The blood vessels around the areas were congested and there was also proliferation of new blood capillaries within the zone of fibroplasia. The cyst contained a single metacestode with cuticle and muscle strands typical of *T. taeniaeformis strobilocercus*.

Histopathological studies of the *T. taeniaeformis* metacestode found in the rat liver tissues revealed infiltration of mononuclear cells, which mainly comprised of lymphocytes, macrophages and occasional eosinophils

with active fibroplasia. This is similar to the report of Al-Najjaar *et al.* (2009) in the liver of white mice, and those of Hanes (1995), McInnes *et al.* (2014) and Moudgil *et al.* (2014) in rats. However, hepatic sarcoma as reported by Al-Jashamy and Islam (2007) and Al-Najjar *et al.* (2009) was not observed in the present slide sections. It was reported that host connective tissue capsule may give rise to sarcomas in older animals typically 12–15 months post-infection. The rats used in this study were of lower age range, hence, the possible reason for the absence of hepatic sarcoma in the present study. Rats are one of the most frequently used experimental animals that are very important for *in-vivo* assays. They are used for preclinical trials and various biomedical researches and sometimes are kept as pets. It is important therefore, to standardize the physical, health and welfare conditions of experimental rats for accuracy of *in-vivo* research, which can be unintentionally affected by parasite infestation. Therefore, the use of animals free from undesirable

pathogen or parasites such as the metacestode of *T. Taeniaeformis* is imperative for reproducibility and standardization of experimental results. Thus, it is necessary to thoroughly screen experimental animals before commencement of any experiment and also to ensure that the animals are kept free from unwanted infections during the experiment.

Adults of *Taenia taeniaeformis* though a normal parasite of cat, but also recovered from the intestine of humans (Miyazaki 1991, Ekahayake *et al.* 1999). The occurrence of *T. taeniaeformis* metacestode in the rats is considered a public health hazard as rodents are valued as a delicacy and a source of protein in many communities of developing countries throughout the world.

ACKNOWLEDGEMENT

Authors are thankful to the Technologists in the Histopathology unit of the Department of Veterinary Pathology and Microbiology, Faculty of Veterinary Medicine, University of Nigeria, Nsukka, Nigeria for the slide preparation.

REFERENCES

Al-Jashamy K, Islam MN (2007) Morphological study of *Taenia taeniaeformis* scolex under scanning electron microscopy using hexamethyl dislazane. *Ann Microbiol* 7: 80-83.

Al-Najjar SS, Kadhimand FS, Abdalrziak NA (2009) Parasitological and Pathological study of the *Cysticercus fasciolaris* naturally infested white mice. *Al Anbar J Vet Sci* 2: 43-47.

Bowman DD (2007) Parasites of Cats. In Flynn's Parasites of Laboratory Animals. Baker DG. 2nd edn. Wiley-Blackwell, Oxford. 579.

Chikweto A, Bhaiyat MI, Macpherson CN, Deallie C, Pinckney RD, Richards C (2009) Existence of *Angiostrongylus cantonensis* in rats (*Rattus norvegicus*) in Grenada, West Indies. *Vet Parasitol* 162: 160-162.

Duque BA, Aranzazu D, Agudelo-Flórez P, Londoño AF, Quiroz VH, Rodas JD (2012) *Rattus norvegicus* as

an indicator of circulation of *Capillaria hepatica* and *Taenia taeniaeformis* on a groceries trade center of Medellín, Colombia. *Biomedica* 32: 510-518.

Ekanayake S, Warnasuriya ND, Samarakoon PS, Abewickrama H, Kuruppuarachchi ND, Dissanaik AS (1999) An unusual 'infection' of a child in Sri Lanka, with *Taenia taeniaeformis* of the cat. *Ann Trop Med Parasitol* 93: 869-873.

Hanes MA (1995) Fibrosarcomas in two rats arising from hepatic cysts of *Cysticercus fasciolaris*. *Vet Pathol* 32: 441- 444.

Kataranovski M, Mirkov I, Belij S, Popov A, Petrovic Z, Gaci Z (2011) Intestinal helminths infection of rats (*Ratus norvegicus*) in the Belgrade area (Serbia): the effect of sex, age and habitat. *Parasite* 18: 189-196.

Malsawmtluangi C, Prasad PK, Biswal DK *et al.* (2011) Morphological and molecular identification of the metacestode parasitizing the liver of rodent hosts in bamboo growing areas of Mizoram, Northeast India. *Bioinformation* 7: 393-399.

McInnes E, Kohn H, Carmichael I, Rsamussen L, Noonan D, Robert S (2014) Larvae of *Taenia taeniaeformis* in the liver of a laboratory rat (*Rattus Norvegicus*). *Ann Clin Path* 2(3): 1028.

Miyazaki I (1991) An Illustrated Book of Helminth Zoonoses. No 62. Tokyo, SEAMIC Publication. 494.

Moudgil AD, Singla LD, Gupta K, Daundkar PS, Vemu B (2016) Histopathological and morphological studies on natural *Cysticercus fasciolaris* infection in liver of Wistar rats. *J Parasitic Dis* 40(2): 255-258.

Seong JK, Huh S, Lee JS, Oh YS (1995) Helminths in *Rattus norvegicus* captured in Chunchon, Korea. *Korean J Parasitol* 33: 235-237.

Singh YD, Arya RS (2015) Clinico-pathology, diagnosis and management of *Cysticercus fasciolaris* and *Hymenolepis diminuta* co-infection in Wistar rats, *Vet World* 8(1): 116-120.

***Cite this article as:** Onoja RI, Idika IK, Ezeh IO, Abiazute CN (2017) Histopathological detection of the larval stage of *Taenia taeniaeformis* (Strobilocerci) and its associated lesions in liver of laboratory rats: case report. *Explor Anim Med Res* 7(1): 97-99.