

Short Communication

PNEUMOCONIOSIS IN A SPOONBILL - A CASE REPORT

Shivaji Bhattacharya¹, B. Dutta, J. Mukherjee, M. Chowdhury,
B. B. Roy and Malay Mitra

ABSTRACT : Pneumoconiosis has been identified in an adult dead spoonbill (*Platalea leucorodia*) from a Zoo in Kolkata, West Bengal, India. An environmental automobile pollutants present around that ambient may be the cause of pneumoconiosis.

Key words : Pneumoconiosis, Spoonbill.

Spoonbill (*Platalealeucorodia*), under the family *Threskiornithidae* are protected in India by the Wild Life (Protection) Act, 1972 and enlisted under Schedule IV of the Act. These are little larger than domestic duck, about 45 cm in height. Neck and legs are elongated and body is covered with white feathers. Bill (beak) is black mixed with white in colour, elongated, flat and frontal part of the beak is wider and spoon like appearance (Ali & Ali 1967).

Pneumoconiosis is a condition caused by inhalation of organic or inorganic dust particles usually over long period of time. Pneumoconiosis in birds is rare (Smith *et al.* 1973) and the report in wild birds specially in spoonbill is scanty.

An adult dead spoonbill was brought to Disease Investigation Laboratory, Institute of Animal Health & Veterinary Biologicals(R&T),

Kolkata for postmortem examination from a Zoo in Kolkata with the history of anorexia, dullness, respiratory distress along with diarrhoea. The bird was treated symptomatically with broad spectrum antibiotic but succumbed to its illness.

During gross pathological examination, the carcass was dehydrated (Fig.1), having blackish spots in the lungs especially at the lower borders of them (Sastri 2001) with some inflammatory changes. Part of the lung tissue was grey, mottled and blackish in colour (Thomson 1978, Vegad 2007), may be due to deposition of significant amount of carbon particles (Fig.2). Trachea was slightly congested and having some mucus inside. Among other visceral organs, the heart revealed engorgement of blood in right chambers along with few petechiation on musculature with hydropericardium (Fig.3).

Institute of Animal Health & Veterinary Biologicals(R & D), Kolkata –700 037, West Bengal, India.
¹*Assistant Director, ARD (Vety.), LB-2, Salt Lake City, Kolkata – 700 098, West Bengal, India.*

Pneumoconiosis in a Spoonbill - a case report.




Fig.1: Gross-pathological examination of dead Spoonbill.

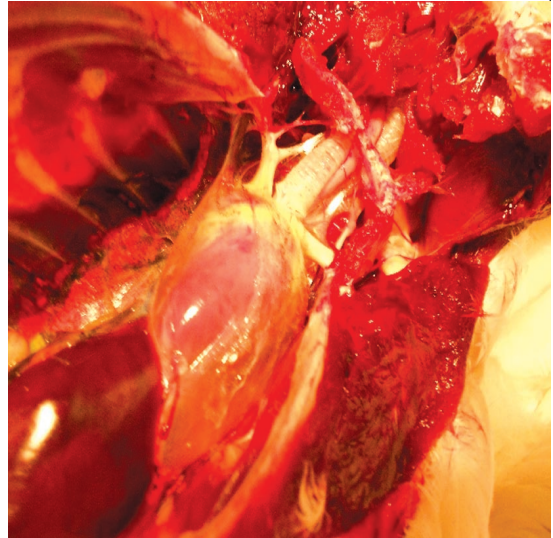


Fig.2: Necropsy of lung tissue appeared as grey, mottled and blackish in colour.

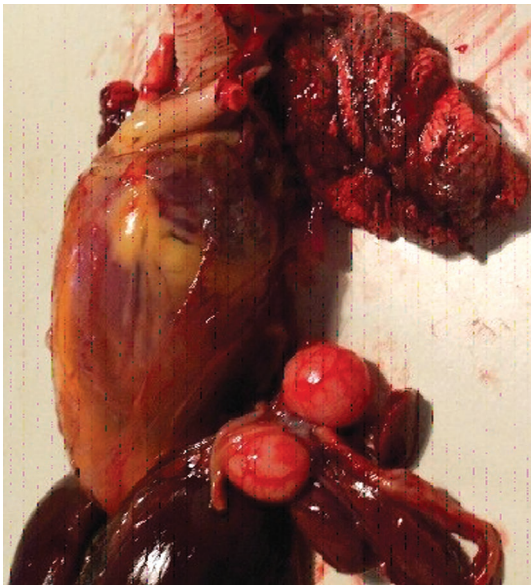

Fig.3: Necropsy revealed hydro-pericardium with few petechiation on musculature.

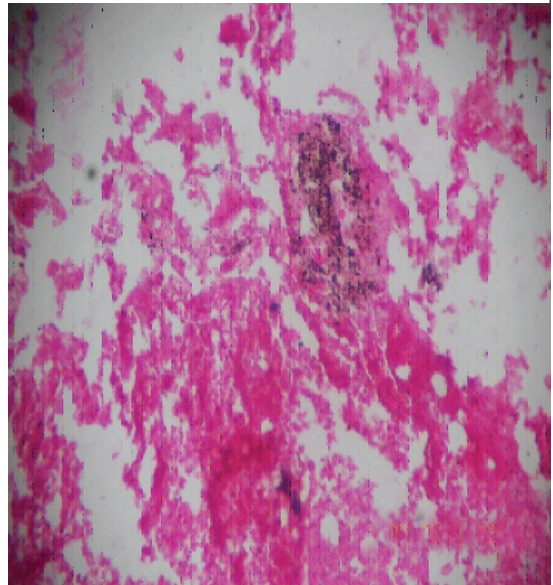


Fig.4: Lung revealed emphysema with dark deposition of carbon particles (H&E stain100X).

The liver and spleen showed focal grayish area of necrosis. Kidney was partly congested, the brain particularly in cerebrum showed few linear haemorrhages and softening of tissue. Intestinal villi and mucosa showed mild congestion with some blackish faecal materials.

In cultural examination, no bacterial growth was detected from heart blood and affected lung tissue in nutrient and blood agar media within 96 hours of inoculation. Microscopical examination revealed no specific helminthic egg or protozoal oocyst in faecal sample and intestinal scraping of dead bird.

In histopathological study, the selected pieces of tissue materials were fixed in buffered neutral formalin solution and after routine histological processing were embedded in paraffin blocks. Sections were cut and stained by Haematoxylin and Eosin (H&E). Sections were examined by light microscopy. Some portions of the lung revealed emphysema containing dark deposit of carbon particles (Dijk *et al.* 2007). Carbon particles appeared as minute black granules seen in among cells or in the cytoplasm, and connective tissue septa (Sastry 2001, Singh 2010). Those particles also seen cluster together in globular mass contain within macrophages (Vegad 2007). In some places carbon particles were extra-cellular and intra-cellular and seen in the alveolar wall as well as bronchiolar and peri-bronchiolar focal mass (James and Zachary 2012). In heart, mild myocardial degeneration with endothelial cell hyperplasia and oedema in myofibril was observed. In liver, hepatocytes showed mild degeneration with scanty Von-Kuffer cell infiltration. Focal petechiation observed in sinusoidal space. In Spleen, focal necrotic area in red pulp region. Splenic vessels showed endothelial hyperplasia. Mild degeneration and focal oedema in renal

parenchyma of kidney was observed. Low grade encephalopathy characterized by focal gliosis, chromatolysis of neurons, mild oedematus changes observed in brain.

Pneumoconiosis in birds' lungs can be related to housing in dusty, enclosed locations and are for the most part incidental lesions at post-mortem (Dzoma and Mulenga-Muradzika 2007). In birds, dust retention produced large granulomas around tertiary bronchi without fibrosis (Brambilla *et al.* 1979) during study of pneumoconiosis in eight avian species in San Diego Zoo. Anderson *et al.* (1968) conducted an experimental study of the effects of turkey house dust on the respiratory tract of turkeys and found little histological change in most cases. Reports of clinically relevant pneumoconiosis are also available, and include that in an eagle, diagnosed on ante-mortem lung biopsy, which was presumably due to exposure to train engine exhaust in a zoological park (Joseph 1996).

In this case, inhalation of soot, an environmental automobile pollutant present around that ambient may be the cause of pneumoconiosis and responsible for pathological changes especially in lungs of the spoonbill.

ACKNOWLEDGEMENT

Authors are thankful to the Director of Animal Husbandry & Veterinary Services, West Bengal for providing necessary facilities.

REFERENCES

Ali S and Ali FA.(1967). *Sadharan Pakhi* (A Bengali version of the original English title: Common Birds). 1st edn. National Book Trust. India. p.29.

Pneumoconiosis in a spoonbill - a casereport.

Anderson DP, Wolfe RR, Cherms FL and Roper WE.(1968). Influence of dust and ammonia on the development of air-sac lesions in turkeys. *Amer. J. vet. Res.* 29: 1049 -1058.

Brambilla C, Abraham J, Brambilla E, Benirschke K and Bloor C.(1979). Comparative pathology of silicate pneumoconiosis. *American J. Pathol.* 96(1): 149-170.

Dijk JE Van, Grays E and Mouwen JMV. (2007). Colour Atlas of Veterinary Pathology. 2nd edn. Saunders Elsevier. USA. p.33.

Dzoma B and Mulenga-Muradzikwa E.(2007). Some disease conditions of aviary birds based on pathologic and clinical findings at the university of Zimbabwe Veterinary hospital and pathology laboratory from 1986- 2004. *Internet J. Vet. Med.* 4 (1).

James JA, Zachary ZA, McDonald D and McGovin G.(2012). Pathologic Basic of Veterinary Diseases. 5th edn. Elsevier. Mosby. Sent Louise. Missouri. p.41.

Joseph V.(1996). Pollutant pneumoconiosis in a golden eagle (*Aquila chrysaetos*). *Assoc. Avian Vet. Proc.* p.227-230.

Sastry GA.(2001). Veterinary Pathology. 7th edn. CBS Publishers & Distributer Pvt. Ltd. New Delhi. p.183.

Singh CDN.(2010). Advance General Pathology of Animal. 1st edn. IBDC Publishers. Lucknow. UP. p.72.

Smith B.L, Poole WSH and Martinovich D.(1973). Pneumoconiosis in captive New Zealand Kiwi. *Vet Pathol.* 10: 94-101.

Thomson N.(1978). General Veterinary Pathology. 1st edn. WB Saunders Co. USA. p.84.

Vegad JL.(2007). Text Book of Veterinary General Pathology. 2nd edn. International Book Distribution Co. Lucknow. UP. p. 61 – 63.

***Cite the article as:** Bhattacharya S, Dutta B, Mukherjee J, Chowdhury M, Roy BB and Mitra M. (2013). Pneumoconiosis in a spoonbill - a case report. *Explor. Anim. Med. Res.* 3(2): 186-189.