

*Short Communication*

## STUDIES ON SCHISTOSOMUS REFLEXUS IN INDIGENOUS CATTLE IN TROPICAL WEST BENGAL, INDIA

D. Jana\* and M. Jana

**ABSTRACT :** During study period of 9 years (January 2000 to December 2008) a total of 195 dystocia cases were attended out of which schistosomus reflexus fetuses were extracted four in number. Detail necropsy studies were made on all four monster fetuses for defining the characteristic features of schistosomus reflexus bovine fetal monstrosity as recorded in tropical West Bengal, India.

**Key Words :** Monster, *Schistosomus reflexus*, Eventration of abdominal organs, Ankylosis.

*Schistosomus reflexus* is one type of fatal congenital malformation of bovine foetus as encountered in dairy cattle throughout the globe. Its defining features include spinal inversion either dorsiflexion or retroflexion of vertebral column with or without ankylosis, joint contractures or limbs ankylosis and exposure of abdominal and or thoracic viscera owing to severe form of abdominal herniation or fissures on ventral or midventral abdominal wall (Denis and Meyer 1965, Cavalieri and Farin 1999, Ozcan *et al.* 2003).

Although a wide variety of fetal monstrosities have been reported from different provinces in India, a very few reports are available in context to bovine fetal monstrosity resembling *Schistosomus reflexus* as encountered in indigenous cattle from West Bengal (Jana and Ghosh 2001). Considering the paucity of available literatures pertaining to

*Schistosomus reflexus* bovine foetal monstrosity, not duly recorded or reported from West Bengal, four fetuses featuring *Schistosomus reflexus* as delivered out of 195 dystocia cases of indigenous cattle during 9 years study period (January 2000 to December 2008) from red laterite and new alluvial soil zones in tropical West Bengal, India is presented in this communication.

Four *Schistosomus reflexus* cases as encountered out of 195 dystocia cases during the study period. Case-1 was delivered by Laparohysterotomy as performed at left lateral paramedian site as per standard procedure and rest three cases (case 2, 3 and 4) were delivered *per vaginum* with judicious traction and standard obstetrical procedures. Following delivery detail post mortem examinations were made on all four specimens (fetal carcass) for defining the features of *Schistosomus reflexus*

---

*Pet Clinic, B-6/215, Congress Road, Kalyani, Nadia, Pin – 741235, West Bengal, India.*

\* Corresponding author.

as reflected on gross morpho-anatomical appearance of the fetus and detailed systemic exploration through necropsy.

The viscera of abdominal region of case -1 fetus was exposed and devoid of parietal peritoneum, and attachment with omentum and mesenterium (Fig. 1). The cavity of the thorax was partially open and covered with a membrane. Foetal heart was normal in shape and size but the lungs were hypoplastic. The organogenesis was complete but the skin, musculature and peritoneum over the viscera behind the xiphoid cartilage were absent. There were marked distension and over growth of hollow abdominal organs along with marked skeletal defects of both axial and appendicular skeleton characterized by dorsiflexion of foetal spinal column and marked ankylosis of all four limbs.

In case-2 fetus a dead and unorganized foetal monstrosity with a feeling of exposed thoracic and abdominal viscera, exposed foetal limbs were felt *per vaginum* and it was found extremely difficult to remove *per vaginum* with obstetrical procedures. Intending to go for foetotomy under epidural anaesthesia, all exposed foetal viscera was removed (Fig. 3) and thereafter the foetus was removed by moderate traction with profuse lubrication of birth canal (Fig. 2). All foetal viscera of abdomen were found exposed. The cavity of the thorax was open and the lungs were hypoplastic. The limbs were contracted and there was dorsiflexion of foetal spinal column. The case was diagnosed as a *Schistosomus reflexus*. All four limbs were found ankylosed and greatly hypertrophied except one displaced, short, thin and deformed limb (Fig. 2).

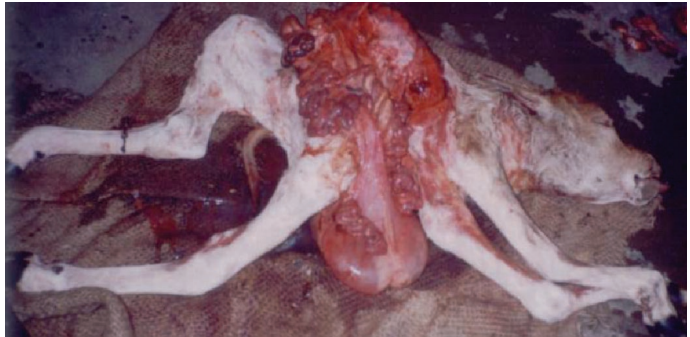
Gross examination of the dead foetal monster as retrieved from a dystocia case,

delivered *per vaginum* with judicious obstetrical procedure revealed over grown and highly distended abdominal viscera, retroflexed and ankylosed vertebral column and partial ankylosis of all four limbs resembling *Schistosomus reflexus* (Fig. 4 and 5) in case -3. The abdominal and pelvic cavities were absent. Thoracic cavity was also open and covered with a membrane. The lungs were hypoplastic and the ribs were everted. Liver was found enlarged with cystic lesions containing yellowish fluid. Distended bowels or enterales as well as rumen were filled with sticky yellowish fluid. The sex of the foetus could not be ascertained as there was no sexual organ or appendages to define the sex.

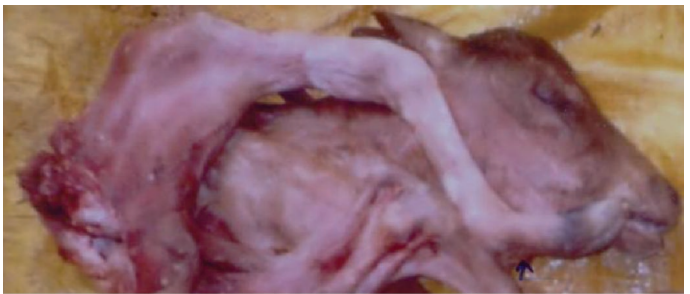The still born monster foetus as removed with judicious traction had grossly normal head and neck region in case-4. The thorax although deformed and laterally compressed, had intact diaphragm and the thoracic organs remained inside the thoracic cavity. There was eventration of all abdominal organs and had marked anomaly of alimentary tract. Skin and musculatures over the abdominal viscera were completely absent. The calf revealed arching of the back at thoraco-lumber junction and hind limbs with deformed rudimentary pelvis brought forward leaving the pelvic and abdominal organs exposed. The lungs were very small and heart was normal in size and shape. The liver was abnormal in shape but noncystic. The rumen was distended and was filled with straw colored fluid. The limbs were partially ankylosed. The calf had thus close resemblance to *Schistosomus reflexus*.

The observation described in this paper like eventration of abdominal viscera, gross anomaly in alimentary system, marked skeletal defect with dorsiflexion, retroflexion or

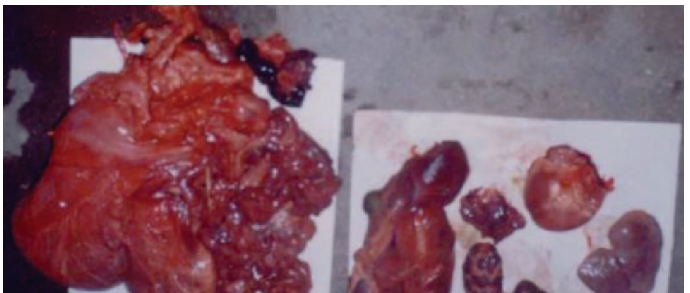inversion of spines and ankylosis of limbs etc. had close resemblance to typical *Schistosomus reflexus* reported by other workers (Leipold and Dennis 1986, Saperstein 1993, Cavalieri and Farin 1999). Roberts (1982) suggested that *Schistosomus reflexus* may accompany cystic lesions in liver and sometimes rumen which might be filled with fluid. In our study great distension of hollow organs were noticed in case-3 and rumen was filled with sticky yellowish fluid in case 3 and 4. The liver enlarged with cystic lesions was also encountered in case-3. Hypoplastic lungs were evident in all four monster foetus which was also observed by others (Dennis and Myer 1965, Ozcan *et al.* 2003). The literature contains many references to the foetal *Schistosomus reflexus* causing dystocia in cattle which necessitated fetotomy or caesarian section (Padma Rao *et al.* 1993, Srivastava *et al.* 1998, Jana and Ghosh 2001). But in our study it was found that except in case-1, rest-three cases were relieved pervaginum under epidural anaesthesia adopting judicious obstetrical procedures and that could be made possible with profuse lubrication of birth passage making judicious traction, removing exposed abdominal viscera (as in case no.2) and above all owing to small underweight *Schistosomus reflexus*. According to Dennis and Meyer (1965) this kind of foetal monstrosity considered to be a severe



**Fig. 1 : *Schistosomus reflexus* bovine foetal monster with ankylosis of limbs and ectopic viscera.**

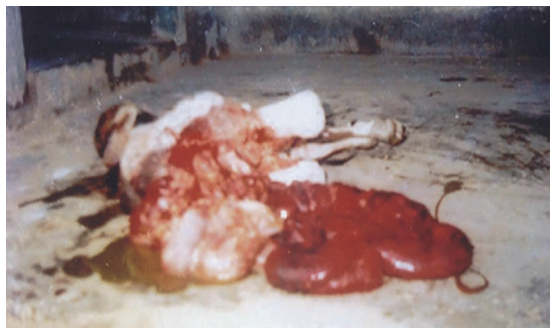

**Fig. 2 : *Schistosomus reflexus* bovine foetal monster with dorsiflexion of foetal spinal column. (All the visceral organs removed during obstetrical procedure).**



**Fig. 3: Thoraco abdominal visceral organs as removed from the monster foetus No. 2.**

form of an abdominal hernia associated with skeletal defects and this arises in early embryonic life when the lateral edges of the germinal disc are reflected dorsally instead of ventrally to form the body cavities.



**Fig. 4:** *Schistosomus reflexus* bovine foetal monster with retroflexed and ankylosed and ectopic evisceration.



**Fig. 5:** Bovine foetal monster resembling *Schistosomus reflexus* with eventration of all abdominal organs (viscera ectomised).

The cause of *Schistosomus reflexus* still remains ambiguous. However, many authors are in opinion that genetic factors and or interplay of multiple genes could influence on the occurrence of such monstrosity (Roberts *loc. cit.* Leipold and Dennis 1986, Jana and Ghosh 2001). Four *Schistosomus reflexus* cases presented in this paper belonged to small, marginal farmers of West Bengal where the indigenous cattle were maintained on stray grazing and the cows had been mated closely with related animals. Looking to the aforesaid observations the *Schistosomus reflexus* fetuses appeared to be a sequel of genetic abnormality.

## REFERENCES

- Cavalieri J and Farin PW.(1999).** Birth of a Holstein freemartin calf co-twinning to a *Schistosomus reflexus* fetus. *Theriogenology*. 52: 815-826.
- Dennis SM and Mayer EP.(1965).** *Schistosomus reflexus* in a sheep. *Vet. Rec.* 77: 1386.
- Jana D and Ghosh M.(2001).** Dystocia due to foetal monster with *Schistosomus reflexus* and ectopic viscera – A case report. *Indian Vet. J.* 78: 333-334.
- Leipold HW and Dennis SW.(1986).** Congenital defects affecting bovine reproduction, In Morrow DA.(ed.) current therapy in Theriogenology. W.B. Saunders Co. Philadelphia. p.411.
- Ozcan K, Ozturkler Y, Tuzcu M and Erginosoy S.(2003).** *Schistosomus reflexus* in cattle in Kars province. *Indian Vet. J.* 80: 693-694.
- Padma Rao V, Ram Chandraiah K, Mohan Reddy AR, Venkata Subbiah DO and Chandrasekhar B. (1993).** *Schistosomus reflexus* in a monocephalus Tripus Dibrachias calf. *Indian Vet. J.* 70: 1083.
- Roberts SJ.(1982).** Veterinary Obstetrics and Genital Diseases. 2<sup>nd</sup> edn.(Indian edn.) CBS Publishers and Distributors. India. p.284.
- Srivastava KK, Sharma AK, Ahlawot SPS and Maithy SK.(1998).** *Schistosomus reflexus* with perosomus elumbis in Holstein Friesian cow. *Indian J. Anim. Reprod.* 19(1) : 75.
- Saperstein G.(1993).** Veterinary clinics of North America. *Food Anim. Practice.* 9: 115.