

Research Article

GROSS MORPHOLOGY AND ENCEPHALIZATION QUOTIENT OF BRAIN IN MALE AND FEMALE VANARAJA CHICKENS AT DIFFERENT AGES

Kuldeep Kumar Panigrahy^{1*}, Kumaresh Behera², Arun Kumar Mandal³, Kamdev Sethy⁴, Sasmita Panda⁵, Sidharth Prasad Mishra⁶, Anup Kumar Singh¹, Sangram Keshari Sahu¹

Received 16 February 2017, revised 05 April 2017

ABSTRACT: One hundred fifty day-old sexed Vanaraja chicks (75 male + 75 female) were taken as experimental birds. Dissection of cranium was performed carefully and study of gross morphology of brain was undertaken at different ages in male and female birds. The brain in situ appeared like a 'spade' symbol in playing card but it appeared rather wider and globular in both sexes. The cerebrum varied from pear to oval or even globular in shape in both sexes. On dorsal view, the cerebral hemispheres appeared moderately convex and smooth surfaced. On ventral surface, ill-developed olfactory lobes were observed anteriorly on either side of the median fissure in both male and female Vanaraja birds. The hippocampus was located transversely to the posterior one third parts of both cerebral hemispheres. Duncan's EQ ranged from 5.801 ± 0.514 (T3-Male) to 5.944 ± 0.451 (T1-Female) on 21st day. There was significant decrease ($p < 0.05$) in EQ from Day 21 to 42 across all the groups. On 84th day, the range of EQ was 1.346 ± 0.115 (T3-Male) to 1.444 ± 0.114 (T1-Female). In case of Cuvier's EQ, on 21st day the value ranged from 35.079 ± 0.288 (T2-Male) to 36.531 ± 0.312 (T3-Female). There was significant reduction ($p < 0.05$) in Cuvier's EQ value from Trial-I (21st day) to Trial-II (42nd day). Again, a significant decrease in EQ value was evident from Trial-III (63rd Day) to Trial-IV (84th Day). On 84th day, the EQ ranged from 15.607 ± 0.123 (T3-Male) to $16.038c \pm 0.125$ (T2-Male). Duncan's formula had very high correlation coefficient with brain length (0.915). There was also very high degree correlation between brain weight and body weight (0.963). Brain weight and neuronal size are also highly correlated (0.902). Neuronal size and brain volume are also having a high correlation (0.902). The EQ values had medium correlation with neuronal size (0.701 for Cuvier's Formula and 0.713 for Duncan's formula). Duncan's and Cuvier's value had a very high degree of correlation (0.998).

Key words: Brain, Morphology, Cerebellum, Dorsal, Ventral, Encephalization Quotient.

INTRODUCTION

Avian brain study is an emerging field in present era of biological studies. Study on avian brain will usher a path to the neuro-anatomists to investigate general principles of the nervous system in respect to development behavior, physiology, anatomy and molecular biology.

The avian models can be used to decipher many unknown facts about neuronal mechanism underlying various cognitive functions such as memory, learning, consciousness and attention (Shimizu 2009). Brain morphology reflects the cognitive capacity, behavioral repertoire and evolutionary process of a species

¹Division of Livestock production management, ICAR-National Dairy Research Institute, Karnal, India.

²Department of Livestock Production and Management, College of Veterinary Science and A.H., Odisha University of Agriculture and Technology, Bhubaneswar, India.

³Department of Anatomy, Histology and Embryology, West Bengal University of Animal and Fishery Sciences, 37 K.B. Sarani, Kolkata- 700 037, India.

⁴Department of Animal Nutrition, College of Veterinary Science and A.H., Odisha University of Agriculture and Technology, Bhubaneswar, India.

⁵Department of Livestock Production and Management, West Bengal University of Animal and Fishery Sciences, 37 K.B. Sarani, Kolkata- 700 037, India.

⁶Department of Animal Genetics and Breeding, West Bengal University of Animal and Fishery Sciences, 37 K.B. Sarani, Kolkata- 700 037, India.

Corresponding author. e-mail: kul.pani42@gmail.com

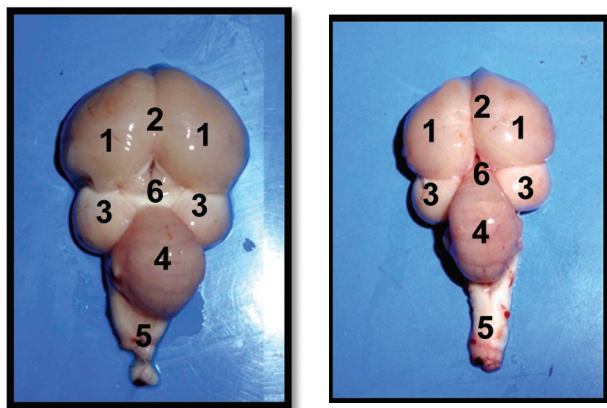


Fig. 1. Photograph of the brain (dorsal view) showing different gross anatomical parts.

1- Cerebral hemisphere, 2 - Longitudinal fissure, 3 - Optic lobe, 4 - Cerebellum, 5 - Medulla oblongata, 6 - Pineal gland in 10 weeks old Male and female Vanaraja birds respectively.

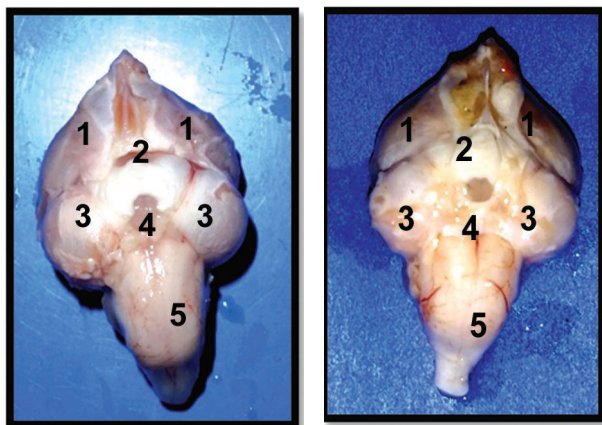


Fig. 2. Photograph of the brain (ventral view) showing different gross anatomical parts.

1- Cerebral hemisphere, 2- Optic chiasma, 3- Optic lobe, 4- Hypothalamus, 5- Medulla oblongata in 10 weeks old male and female Vanaraja birds respectively.

(Cauchoix and Chaine 2016). Avian hippocampus plays a key role in spatial learning, cognitive memory and navigation were well established (Srivastava *et al.* 2007). However, the literature on systematic and comparative avian brain morphological changes of poultry there is no available report in this regard. The present study was accordingly planned to study in detail about brain morphology with respect to age in male and female Vanaraja birds. Cerebellum is the major part of the hind brain (rhombencephalon) which is large, laterally compressed and wedge-shaped structure posterior to the cerebrum. The present study was accordingly planned to correlate the brain morphology with cognition and memory by calculating encephalization quotient and correlation of this with other body parameters and neuronal length. The study of animal cognition is a growing one, with increasing dialogue among researchers in different academic fields. Cognition may play a useful criterion to select bird in future breeding program, to obtain birds with higher development capacity.

MATERIALS AND METHODS

One hundred fifty-day-old sexed backyard chicken Vanaraja chicks (75 male + 75 female) were utilized as experimental birds. The birds were procured from the Central Poultry Development Organization (CPDO) East Region, Bhubaneswar.

Experimental design

The experimental birds were randomly divided in to three groups.

1. Treatment -1 (T1) F: Female Vanaraja – 50 birds
2. Treatment -2 (T2) M: Male Vanaraja - 50 birds
3. Treatment -3 (T3) M+F: (Male + Female) Vanaraja – 25 each = 50 birds.

All birds were housed in deep litter system in three treatments. In each treatment by wire netting partition

Table 1. Encephalization Quotient of the birds across different age groups.

| | Duncan's EQ | | | | Cuvier's EQ | | | |
|--------|-------------------------------|------------------------------|------------------------------|------------------------------|-------------------------------|-------------------------------|-------------------------------|-------------------------------|
| | 21 days | 42 days | 63 days | 84 days | 21 days | 42 days | 63 days | 84 days |
| T1 (F) | 5.944 ^a ± 0.451 | 2.164 ^{b±} 0.191 | 1.873 ^{b±} 0.143 | 1.444 ^{b±} 0.114 | 35.083 ^{a±} 0.263 | 18.928 ^{b±} 0.142 | 18.310 ^{b±} 0.135 | 15.706 ^{c±} 0.114 |
| T2 (M) | 5.820 ^a ± 0.432 | 2.057 ^{b±} 0.164 | 1.796 ^{b±} 0.145 | 1.402 ^{b±} 0.124 | 35.079 ^{a±} 0.288 | 18.800 ^{b±} 0.143 | 18.453 ^{b±} 0.125 | 16.038 ^{c±} 0.125 |
| T3 (F) | 6.143 ^{a±} 0.532 | 2.219 ^{b±} 0.184 | 1.931 ^{c±} 0.145 | 1.401 ^{c±} 0.113 | 36.531 ^{c±} 0.312 | 19.582 ^{b±} 0.167 | 19.024 ^{b±} 0.165 | 15.537 ^{c±} 0.121 |
| T3 (M) | 5.801 ^{a±} 0.514 | 2.052 ^{b±} 0.143 | 1.818 ^{b±} 0.162 | 1.346 ^{c±} 0.115 | 35.390 ^{a±} 0.314 | 18.822 ^{b±} 0.158 | 18.891 ^{b±} 0.162 | 15.607 ^{c±} 0.123 |

Values bearing different superscripts in a row differ significantly (P<0.05).

sixty female and sixty male birds were housed separately. All feedings were done as per BIS specifications. Birds were provided with *ad-libitum* feed and water. For the gross morphological study ten birds from each group were utilized each time at 21, 42, 63, 84 days. So, all totally one hundred twenty birds at different age were slaughtered by cervical dislocation technique (Batah *et al.* 2012). The head of the birds under study were carefully separated at the level of second cervical vertebrae. The separated head of these birds were taken immediately to the department of Veterinary Anatomy and Histology for collection of brain samples. The cranial cavity was cut open very carefully with the help of scissors, forceps and scalpel. Then nasal bones and temporal bones were severed rostrally and laterally by the help of bone cutter. These separations were done up to the level of base of skull. All cranial nerve attachments were cut gently to separate the intact brain from in-situ after detaching it from the spinal cord at the level of foramen magnum. The intact brain was removed from the cranial cavity after detaching it from the spinal cord at the level of foramen magnum. Then the meninges of brain were separated. After the collection, the intact whole brain samples were cleaned (washed) in normal saline solution and detail morphological studies were undertaken.

Calculation of Encephalization Quotient (EQ)

Encephalization Quotient (EQ) was calculated by two formulae.

* Cuvier's formula

$$EQ = E/S$$

Where,

E = brain weight

S = body weight

* Duncan's formula

$$EQ = M_B/EM_B$$

Where

M_B = Mass of brain

EM_B = Expected mass of brain

$EM_B = 0.12 * (\text{body mass})^{2/3}$

RESULTS AND DISCUSSION

After collection of intact brain from the cranial cavities of the birds, the meninges were carefully removed. Then the comparative gross anatomical features of the brain were studied in male and female Vanaraja birds at 10 weeks old age. Vanaraja birds showed a little variation in gross morphology and shape of whole brain at their different ages of growth period. Also, a same trend was seen in between male and female birds. However, the brain appeared comparatively wider and globular in most

of the Vanaraja birds. The brain *in situ* appeared like a 'spade' symbol in playing card but it appeared rather wider and globular in both male and female Vanaraja birds. Earlier findings about morphology of brain revealed that general shape of the avian brain was more or less triangular or pear shaped. So, our finding was in support with previous observations made in locally bred chicken (Batah *et al.* 2012) and in barn owl (Abd-Alrahman 2012).

Cerebrum, cerebellum and medulla oblongata were three major subdivisions of brain in both male and female brain specimens. The cerebrum was by far the largest part of the brain, and it comprised of two symmetrical (right and left) halves called cerebral hemispheres. The cerebrum varied from pear to oval or even globular in shape in both sexes of Vanaraja birds. The cerebral hemispheres were wedged between the large eyes, specifically it's anterior (rostral) narrow tube. The posterior or caudal part gradually became wider (Fig. 1). These observations were in support with previous works who reported similar findings in white crested and uncrested chicken breeds (Frahm and Rehkemper 1998). The shape of cerebral hemisphere (cerebrum) was almost similar to the shape of entire brain. Abd-Alrahman (2012) reported similar findings on shape of brain in barn owl, Batah *et al.* (2012) in locally bred chicken and Dhage *et al.* (2013) in migratory bird. The cerebral hemisphere shape is an important determining factor for the shape of entire brain. Kawabe *et al.* (2013) reported that shape of cerebral hemisphere varies with size and shape of the large eye and orbit. There may be individual breed variation in brain shape.

On dorsal view, the cerebral hemispheres appear moderately convex and smooth surfaced in both male and female Vanaraja birds because of the absence of usual convolutions or elevations (gyri) and depression or grooves (sulci). Similar type finding was observed in *Sturnus vulgaris* birds (Dhage *et al.* 2013).

The apparently closely apposed cerebral hemispheres were separated by a media (longitudinal) inter hemispheric fissure (groove). A small transverse fissure separated the cerebrum from the cerebellum (Fig. 1). The feebly developed rhinencephalon had relatively smaller, ill-defined olfactory bulbs at the rostral (anterior) pole of the hemispheres. The olfactory bulbs in most of the specimen were either distorted or severed during dissection because of the intimate connection of olfactory nerves (neurons). There was a slight elevation called sagittal eminence (wulst) on either side of the median fissure. Its lateral curved margin was demarcated from the rest of the cerebral hemisphere by an indistinct groove called valleculla. This finding was in contrary to previous findings who observed a distinct and very large valleculla in Ostrich (Peng *et al.* 2010).

Table 2. Correlation Matrix of body weight, encephalometric parameters, Encephalization Quotient and neuronal size.

| | Body weight | Brain weight | Brain volume | Brain length | Brain width | Neuronal size | Duncan's EQ | Cuvier's EQ |
|---------------|-------------|--------------|--------------|--------------|-------------|---------------|-------------|-------------|
| Body weight | 1 | | | | | | | |
| Brain weight | 0.963 | 1 | | | | | | |
| Brain volume | 0.823 | 0.865 | 1 | | | | | |
| Brain length | 0.944 | 0.944 | 0.849 | 1 | | | | |
| Brain width | 0.859 | 0.951 | 0.819 | 0.855 | 1 | | | |
| Neuronal size | 0.883 | 0.917 | 0.902 | 0.854 | 0.844 | 1 | | |
| Duncan's EQ | 0.888 | 0.839 | 0.698 | 0.915 | 0.703 | 0.713 | 1 | |
| Cuvier's EQ | 0.889 | 0.824 | 0.681 | 0.904 | 0.680 | 0.701 | 0.998 | 1 |

The sagittal eminence became flattened that continued to the posterior pole of the hemisphere. On dorsal view, the large optic lobes (tectum) were not entirely visible because of the oblique orientation of brain. But in lateral view of mid brain optic lobes *i.e.* tectum was appeared as a prominent spherical body. The finding was corroborated well with the previous observations (Husband and Shimizu 1999). However, these optic nerves were relatively very large, prominent, spherical or round bodies of the mid brain, partially hidden under the caudo-ventral part of the cerebra hemisphere. A small pineal body (epiphysis cerebrae) was wedged between the cerebral hemispheres at the posterior end of the median fissure just in front of the cerebellum. Its narrow stalk was attached with the roof of diencephalon.

Cerebellum is the major part of the hind brain (rhombencephalon) which is large, laterally compressed and wedge-shaped structure posterior to the cerebrum but the falcons birds have a small cerebellum which contradicts our study (Sultan 2005). Its middle part was comparatively wider than both the narrow ends (anterior and posterior). Its anterior end fitted into a notch which was 'V' shaped between the caudal poles of the both the optic lobes and cerebral hemispheres (Fig. 1). The cerebellum overlaid most of the medulla oblongata. The cerebellum had a central vermis and two lateral lobes (flocculi). The surface was subdivided into many folds (folia) by a number of transverse grooves or sulci.

On ventral surface, ill-developed olfactory lobes were observed anteriorly on either side of the median fissure in both male and female Vanaraja birds but an opposite finding were also observed in white crested polish chicken which have well developed olfactory lobe (Frahm and Rehkamper 1998). Just behind the posterior part of the median fissure there was optic chiasma ('X'-shaped point of exchange or criss-crossing of optic nerve fibers from respective optic nerves). This was followed immediately by part of diencephalon (hypothalamus along with its

connection of pituitary gland or hypophysis) (Fig. 2). However, an intact pituitary gland and its attachments (stalk) was lacking from all the brain specimens collected. One of the most characteristic features of the brain was the presence of two large, spherical to ovoid optic lobes one on each side the transition between the mid brain (mesencephalon) and hind brain (rhombencephalon) was not clearly understood. The mid brain blended directly with the medulla oblongata posteriorly. The medulla oblongata was almost occupied dorsally by the cerebellum (Fig. 2).

The hippocampal area (hippocampus) was located on the transverse made along the posterior one third parts of both cerebral hemispheres. It appeared as a dorso-median elevation (protrusion) curving into the narrow, slit-like lateral ventricles on either side (Fig.1). However, earlier report on gross observation could not reveal the exact boundary line of hippocampus (Krebs *et al.* 1996).

Encephalization Quotient

The EQ (Encephalization Quotient) was calculated for each variety in each treatment. The EQ values have been depicted in Table 1. Duncan's EQ ranged from 5.801 ± 0.514 (T3-Male) to 5.944 ± 0.451 (T1-Female) on 21st day. There was significant decrease ($p < 0.05$) in EQ from Day 21 to 42 across all the groups. Sex did not have any significant effect on EQ value. On 84th day, the range of EQ was 1.346 ± 0.115 (T3-Male) to 1.444 ± 0.114 (T1-Female). In case of Cuvier's EQ, on 21st day the value ranged from 35.079 ± 0.288 (T2-Male) to 36.531 ± 0.312 (T3-Female). There was significant reduction ($p < 0.05$) in Cuvier's EQ value from Trial-I (21st day) to Trial-II (42nd day). Again, a significant decrease in EQ value was evident from Trial-III (63rd day) to Trial-IV (84th day). On 84th day, the EQ ranged from 15.607 ± 0.123 (T3-Male) to 16.038 ± 0.125 (T2-Male).

From the present finding, it was evident that EQ values varied individually among birds in all 3 groups. Maximum

EQ was observed on day 21. This may be due to higher brain body ratio. During young stage, any bird or animal species tend to possess a larger head to body. Gradually the proportion of head to body reduces. This might be the reason behind a higher EQ. Gradually on day 42, 63 and 84, the EQ values in both the formulae decreased. EQ is considered as a reliable index for intelligence of individual (Chatterjee 2015, Zeigler-Hill *et al.* 2015). EQ value are more or less comparable with those recorded in different avian species (Chatterjee 2015, Zeigler-Hill *et al.* 2015), who considered the crow as the most intelligent amongst all the birds studied as regards to the EQ. Similar observations were made in the present study, where the said female birds emerged as the superior one as regards to cognitive behavior and intelligence. The present findings are also similar to the range of values observed by Hurlburt *et al.* (2013) who reported that Encephalization Quotient ranged from 0.357 to 2.986 in 174 extant avian species.

The correlation matrix has been cited in the Table 2. EQ (as per Duncan's formula) has very high correlation coefficient with brain length (0.915). There was also very high degree correlation between brain weight and body weight (0.963). Brain weight and neuronal size are also highly correlated (0.902). Neuronal size and brain volume are also having a high correlation (0.902). The EQ values had medium correlation with neuronal size (0.701 for Cuvier's formula and 0.713 for Duncan's formula). Duncan's and Cuvier's value had a very high degree of correlation (0.998).

It was concluded from above study that morphology of Vanaraja birds in both sexes were similar to other avian species and with advancement of age there was increase in size of gross morphological structures of brain. Duncan's formula is better correlated with brain morphometry than the traditional Cuvier's equation.

REFERENCES

Abd-Alrahman SHA (2012) Morphological and histological study of the cerebrum in a nocturnal bird species (Barn Owl) *Tyto alba*. *Ibn Al-Haitham J Pure Appl Sci* 25(3): 73-87.

Batah AL, Ghaje MS, Aziz SN (2012) Anatomical and Histological study for the Brain of the locally breed chicken (*Gallus domesticus*). *J Thi-Qar Sci* 3(3): 47-53.

Cauchoux M, Chaine AS (2016) How can we study the evolution of animal minds? *Front Psycho* 17: 358-375.

*Cite this article as: Panigrahy KK, Behera K, Mandal AK, Sethy K, Panda S, Mishra SP, Singh AK, Sahu SK (2017) Gross morphology and encephalization quotient of brain in male and female Vanaraja chickens at different ages. *Explor Anim Med Res* 7(1): 28-32.

Chatterjee S (2015) *The Rise of Birds: 225 million years of evolution*. 2nd edn. Johns Hopkins University Press. 89-93.

Dhage SA, Shehan NA, Ali SA, Aziz FH (2013) Anatomical and histological study of cerebral in *Sturnus vulgaris*. *Bas J Vet Res* 12(2): 221-227.

Frahm HD, Rehkemper G (1998) Allometric comparison of the brain and brain structures in the White Crested Polish Chicken with uncrested domestic chicken breeds. *Brain Behav Evol* 52: 292-307.

Husband SA, Shimizu T (1999) Efferent projections of the ectostriatum in the pigeon (*Columba livia*). *J Comp Neurol* 406: 329-345.

Hurlburt GR, Ridgely RC, Witmer LM (2013) Relative size of brain and cerebrum in tyrannosaurid dinosaurs: an analysis using brain-endocast quantitative relationships in extant alligators. Cited in Parrish JM, Molnar RE, Currie PJ, Koppelhus EB (Eds.) *Tyrannosaurid Paleobiology*. Indiana University Press, Bloomington. 134 -154.

Kawabe S, Shimokawa T, Miki H, Matsuda S, Endo H (2013) Variation in avian brain shape: relationship with size and orbital shape. *J Anat* 223(5): 495-508.

Krebs JR, Clayton NS, Healy SD, Cristol DA, Patel SN, Jolliffe AR (1996) The ecology of the avian brain: food-storing memory and the hippocampus. *Int J Avian Sci* 138(1): 34-46.

Peng K, Feng Y, Zhang G, Liu H, Song H (2010) Anatomical study of the brain of the African ostrich. *J Vet Anim Sci* 34(3): 235-241.

Shimizu T (2009) Why can birds be so smart, background, significance and implications of the revised view of the avian brain. *Comp Cogn Behav Rev* 4: 103-115.

Srivastava UC, Chand P, Maurya RC (2007) Cytoarchitectonic organization and morphology of the cells of hippocampal complex in Strawberry Finch (*Estrilda amandava*). *Cell Mol Biol* 53(5): 103-120.

Sultan F (2005) Why some bird brains are larger than other? *Curr Biol* 15: 649-650.

Zeigler-Hill V, Welling L, Shackelford TK (2015) *Evolutionary Perspectives on Social Psychology*. Springer International Publishing, Switzerland. 98-100.